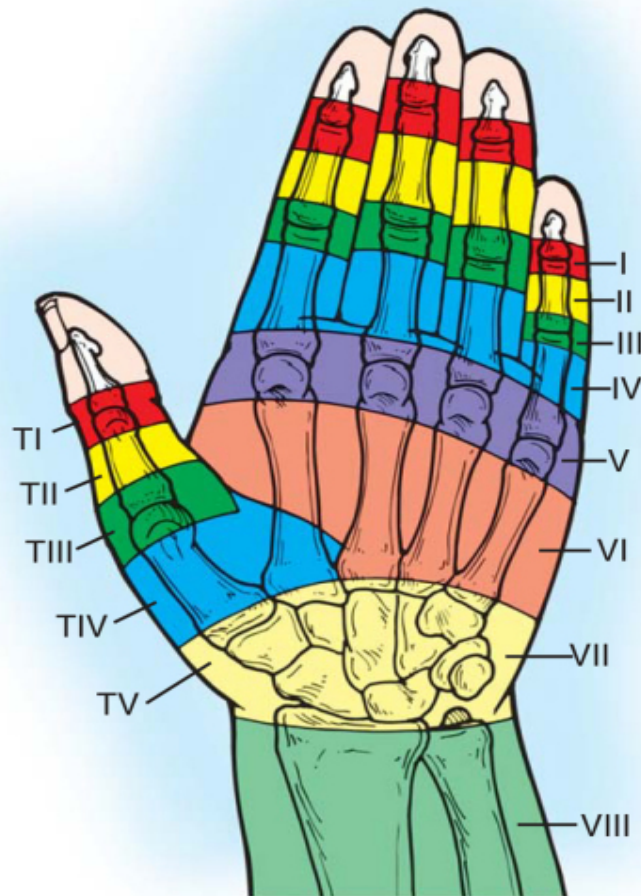


# Ekstensorsenelæsioner/zoneinddeling, farver

Zoneinddeling for ekstensorsener



*Newport ML: Extensor tendon injuries. In Trumble TE, ed: Hand surgery update, 3rd ed, Rosemont, Ill, 2003, American Society for Surgery of the Hand*